



# Foundations EKG II - Unit 8, Case 31

*46 y/o M with PMH of HTN presents with 45 minutes of substernal chest pain that began while playing golf.*

HR: 70      BP: 169/99

RR: 20      O2 Sat: 98 %

## What is your interpretation of the EKG?

History/Clinical Picture

Rate

Rhythm

Axis

P Waves

Q/R/S Waves

T Waves

U Waves

PR Interval

QRS Width

ST Segment

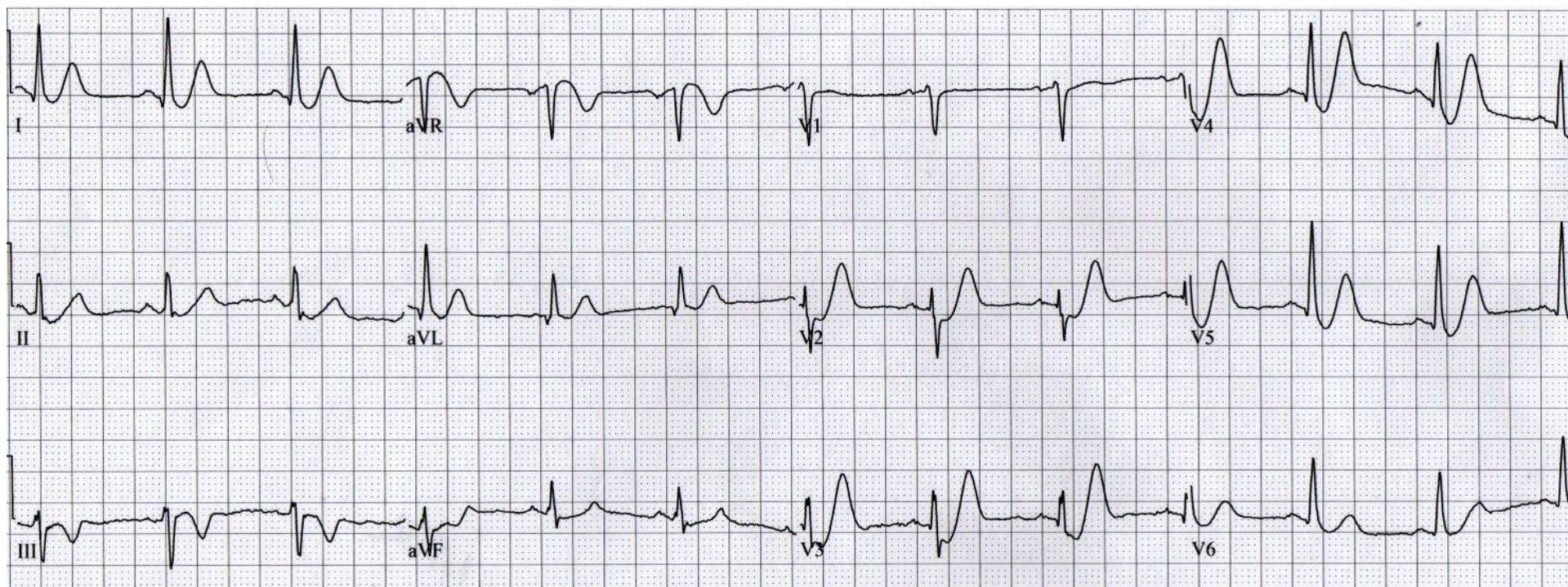
QT Interval

**What is the eponym for the morphology of the ST-T complex seen in this EKG?**

**What does this ST-T morphology signify?**

**How should this patient be managed?**

# Triage EKG



Courtesy of Edward Burns of [Life in the Fast Lane](#)

[Creative Commons License](#)