

Foundations EKG I - Unit 1, Case 3

53 y/o F with history of smoking and hyperlipidemia with chest pain for the past 2 hours.

HR: 95	BP: 130/110
RR: 18	O2 Sat: 96%

What is your interpretation of the EKG?

History/Clinical Picture

Rate

Rhythm

Axis

P Waves

Q/R/S Waves

T Waves

U Waves

PR Interval

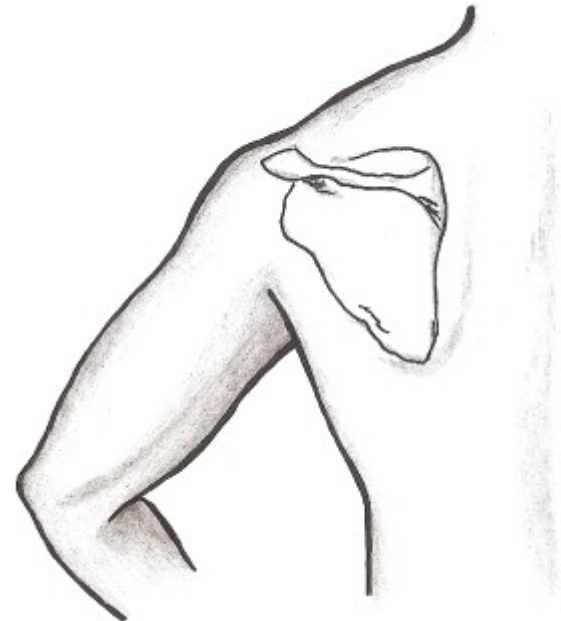
QRS Width

ST Segment

QT Interval

What changes on the standard EKG are suggestive of this diagnosis?

Where should you place leads to get the 2nd EKG?

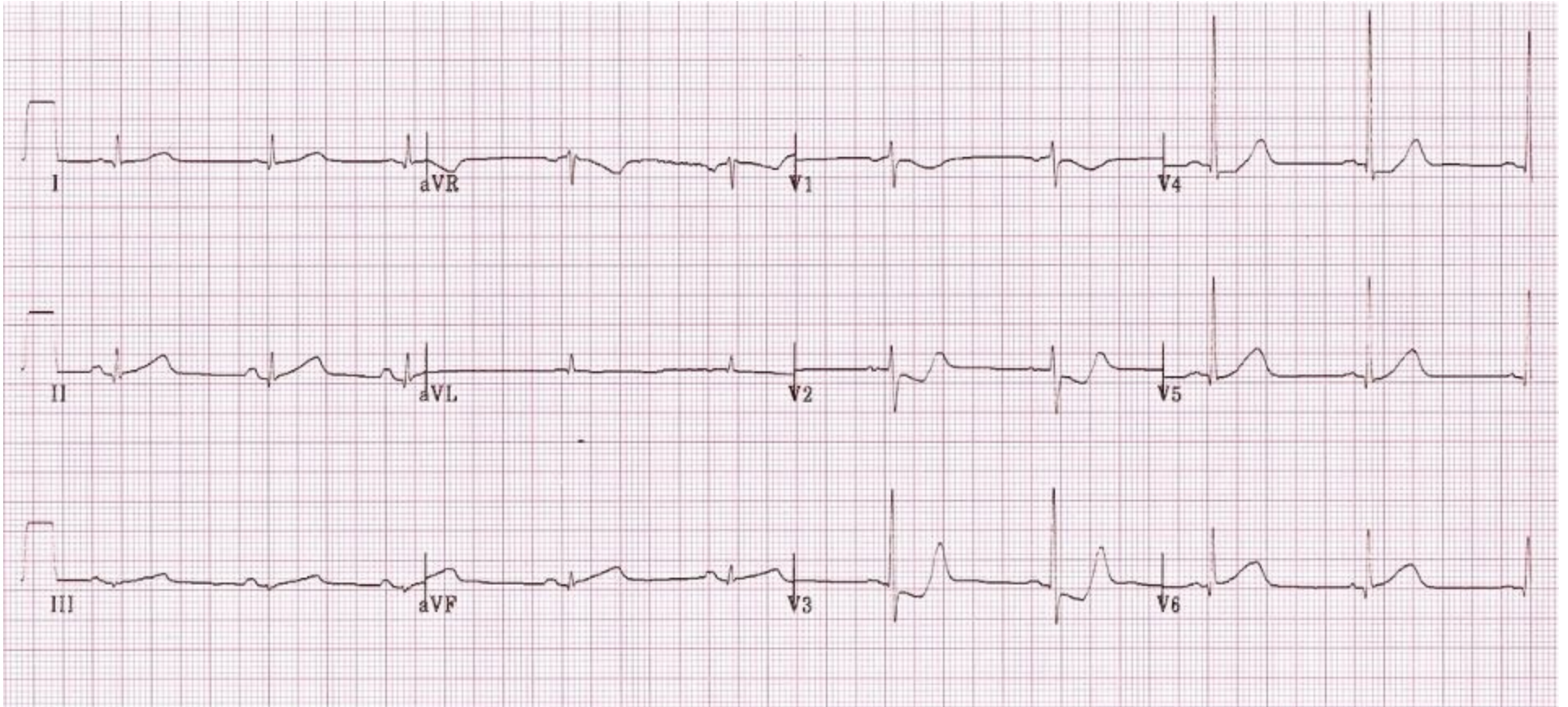


Adapted from http://www.wikilectures.eu/index.php/ECG_Leads

Resources Links: [Life in the Fast Lane](#)

[Dr. Steve Smith's Blog](#)

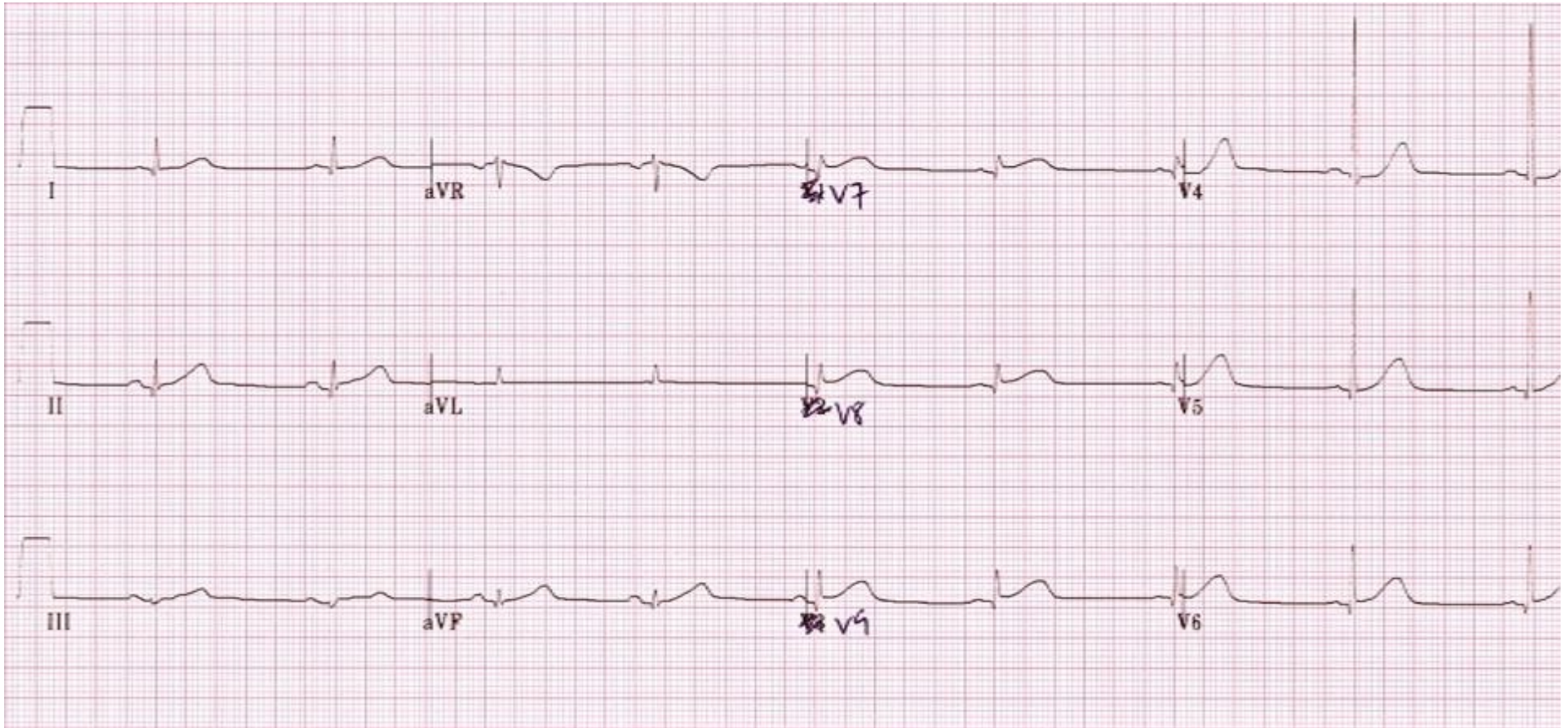
Triage EKG



Courtesy of Edward Burns of [Life in the Fast Lane](#)

[Creative Commons License](#)

Repeat EKG



Courtesy of Edward Burns of [Life in the Fast Lane](#)

[Creative Commons License](#)